

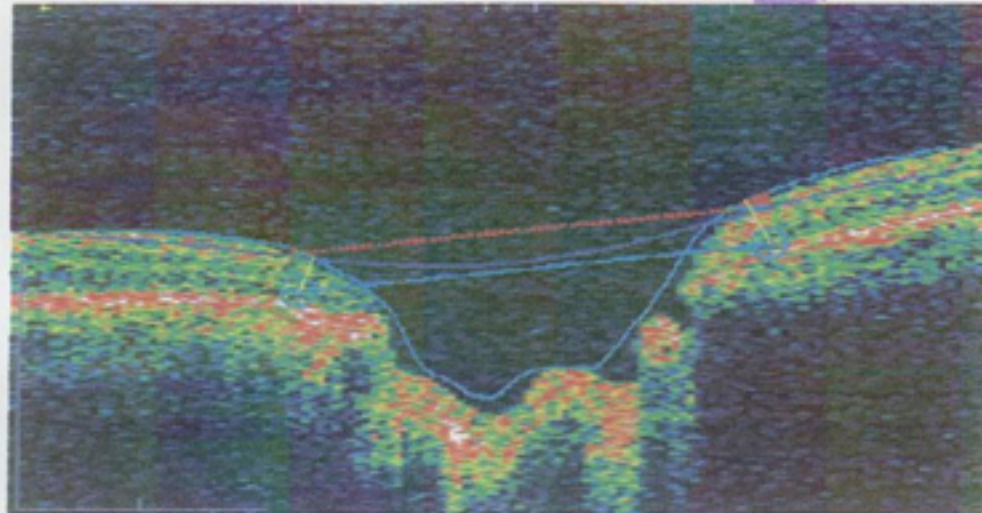
2009 (09)

DOB: 2/13/1941, ID: HOSPITAL CIMA CHIHUAHUA, Female
TECNICO CERTIFICADA POR: VIENNA READING CENTER.

Scan Type: Fast Optic Disc OD

Scan Date: 9/23/2009

Scan Length: 4.0 mm

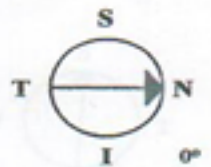

Individual Radial Scan Analysis

Rim Area (Vert. Cross Section): 0.005 mm²
Avg Nerve Width @ Disk: 0.17 mm
Disk Diameter: 1.92 mm
Cup Diameter: 1.76 mm
Rim Length (Horiz.): 0.16 mm

Cup Offset (microns):

150



Signal Strength (Max 10) 9

Optic Nerve Head Analysis Results

Vert. Integrated Rim Area (Vol.) 0.041 mm²
Horiz. Integrated Rim Width (Area) 1.117 mm²
Disk Area 3.183 mm²
Cup Area 2.474 mm²
Rim Area 0.709 mm²
Cup/Disk Area Ratio 0.777
Cup/Disk Horiz. Ratio 0.925
Cup/Disk Vert. Ratio 0.824

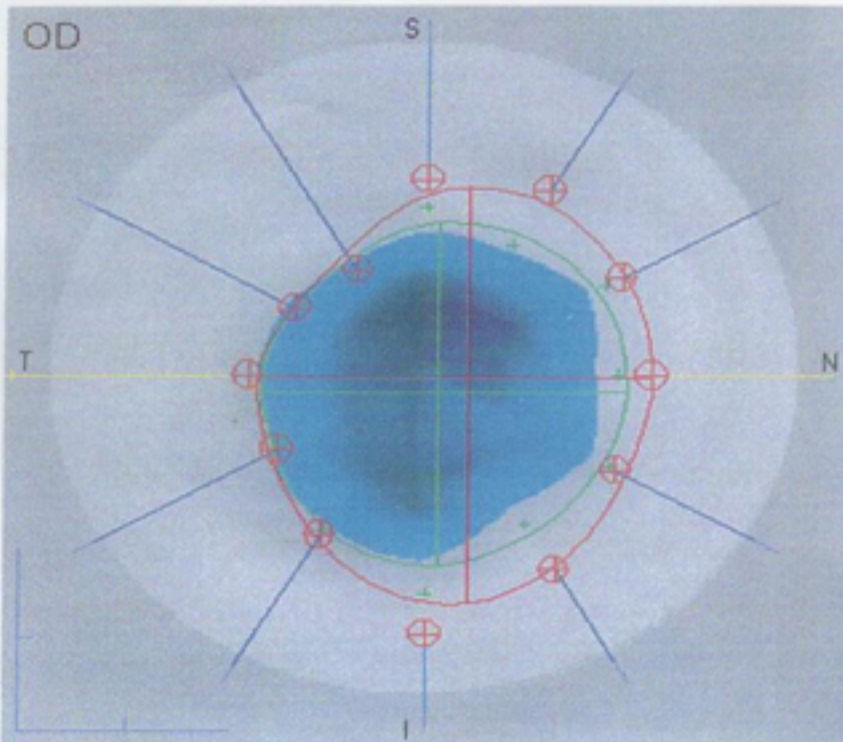
Plot Background:

None Absolute Aligned and Shaded

Cup Offset for Topo (microns): 150

Cup Area (Topo): 2.167 mm²

Cup Volume (Topo): 0.603 mm³



SCAN 1 : Results not Saved.
SCAN 2 : Results not Modified.
SCAN 3 : Results not Modified.
SCAN 4 : Results not Saved.
SCAN 5 : Results not Modified.
SCAN 6 : Results not Modified.

Signature:
